Excretion and osmoregulation

Excretory products and their elimination

Lecture 4

Dr sagar virkar's biology pvt.tuition

Dr sagar virkar's biology pvt.tuition

The **collecting duct system** of the kidney consists of

1. collecting tubules,
2. cortical collecting ducts, and
3. medullary collecting duct.
4. Duct of Bellini /papillary duct

cortical collecting ducts

medullary collecting duct

Duct of Bellini /papillary duct

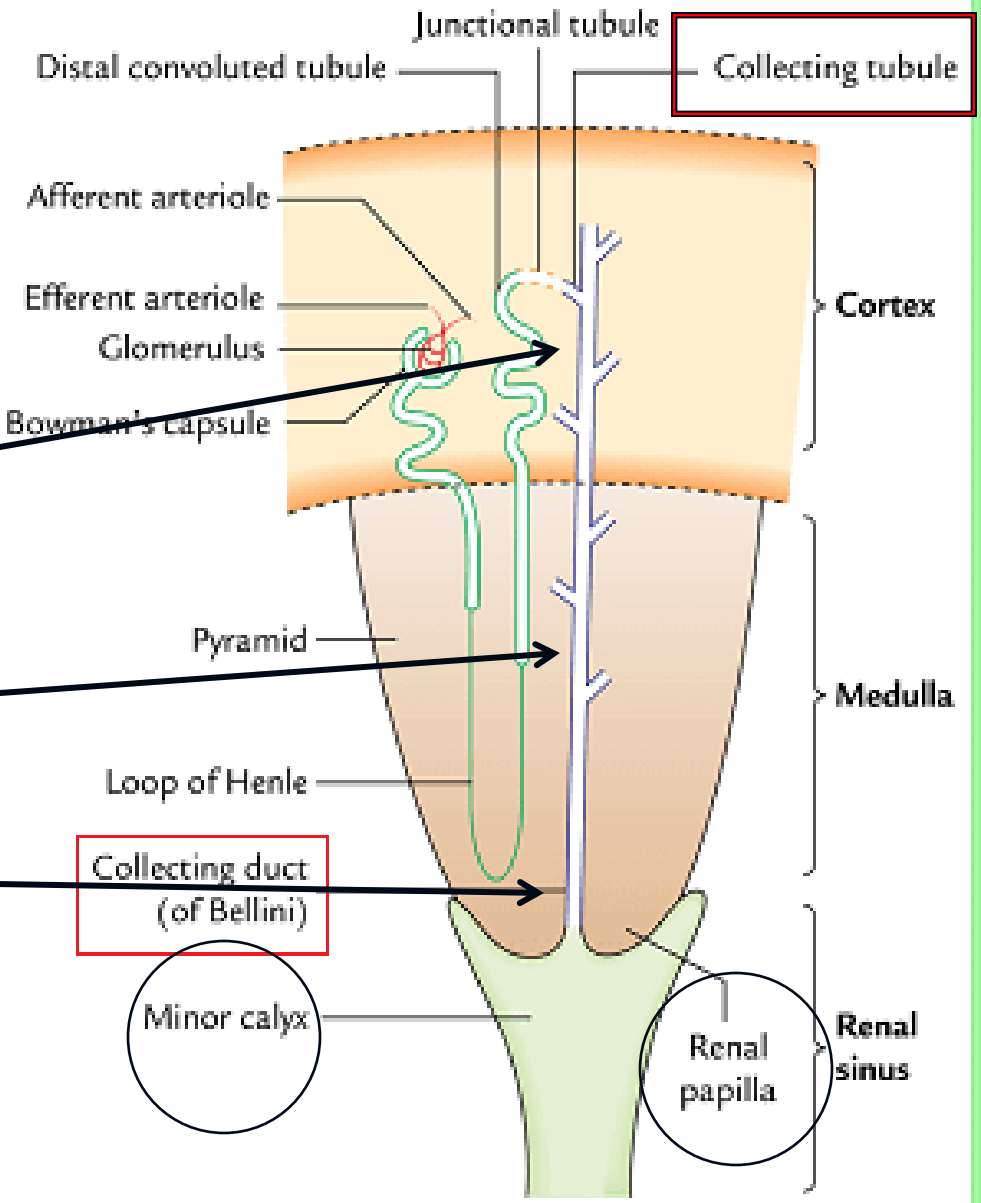

Dr sagar virkar

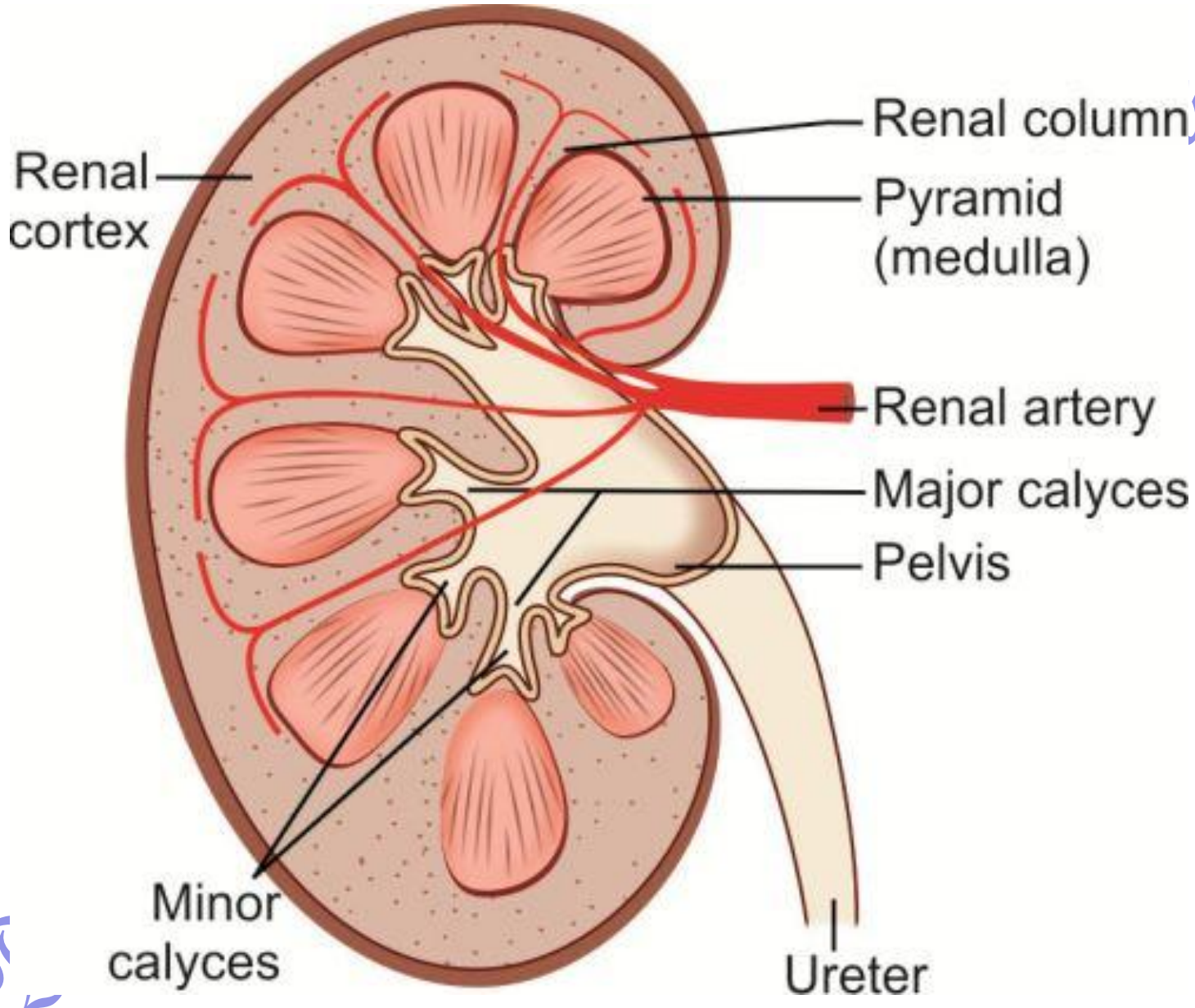
Renal cortex
Renal column
Pyramid (medulla)
Renal artery
Major calyces
Pelvis
Minor calyces
Ureter

1. Bowman's capsule
2. neck
3. PCT –proximal convoluted tubule
4. LOH –loop of henle
5. DCT- distal convoluted tubule
6. CT –collecting tubule
7. Duct of Bellini /papillary duct
8. Minor calyx
9. Major calyx
10. Renal pelvis
11. Ureter
12. Urinary bladder
13. urethra

Dr sagar virkar's biology pvt.tuition

The renal cortex contains the **glomerulus , bowman's capsule,** proximal, and **distal convoluted tubules**.

The renal **medulla** contain the **loops of Henle** and collecting ducts.

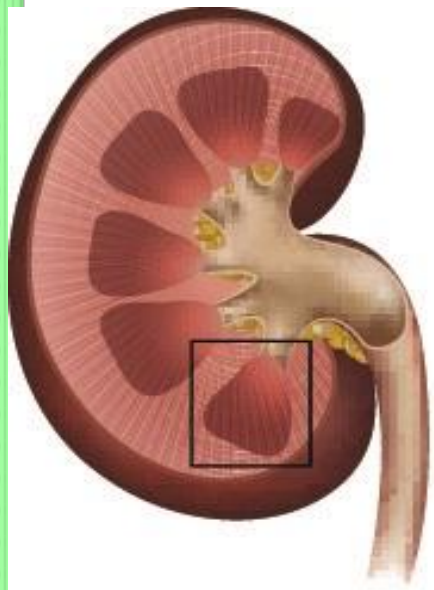

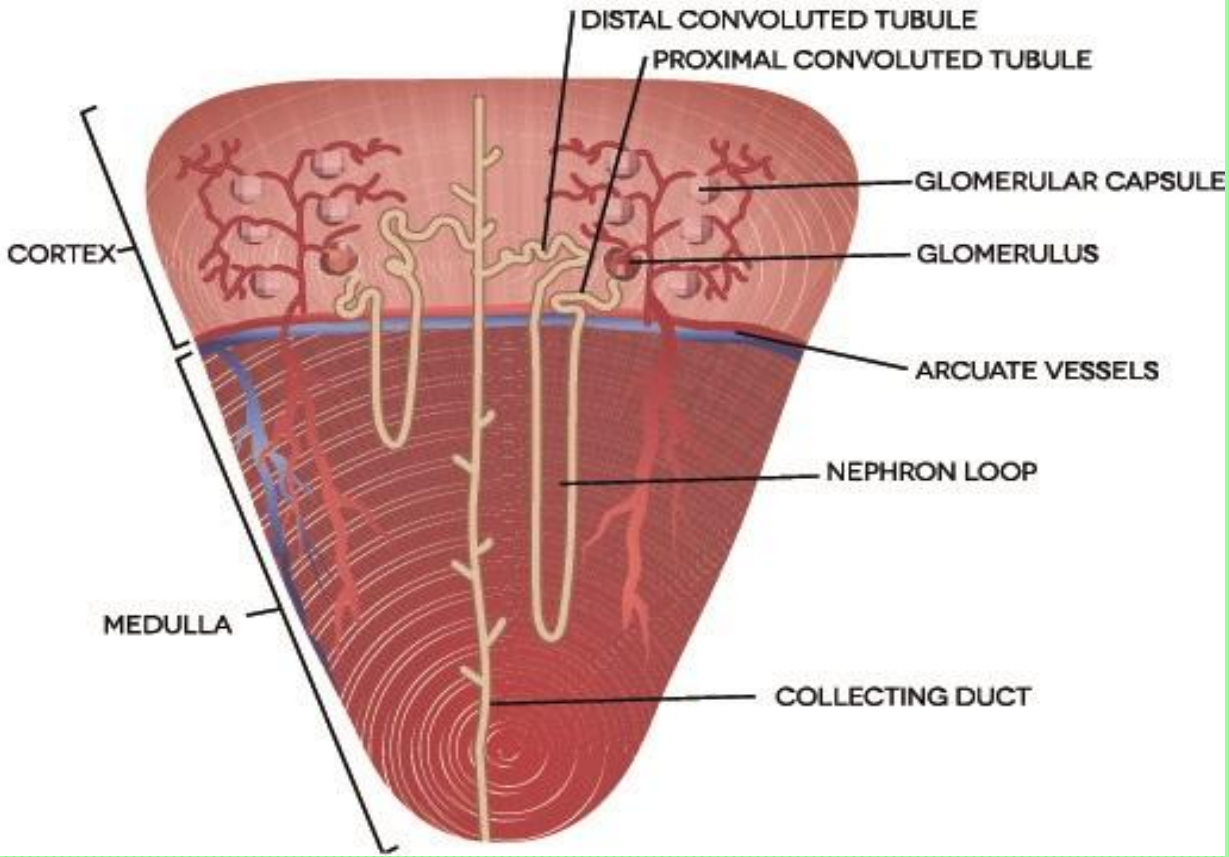

Dr.sagar virkar's biology pvt.tuition

Types of Nephron

1. Cortical Nephrons = shorter Loop of henle
   Extends very little in medulla

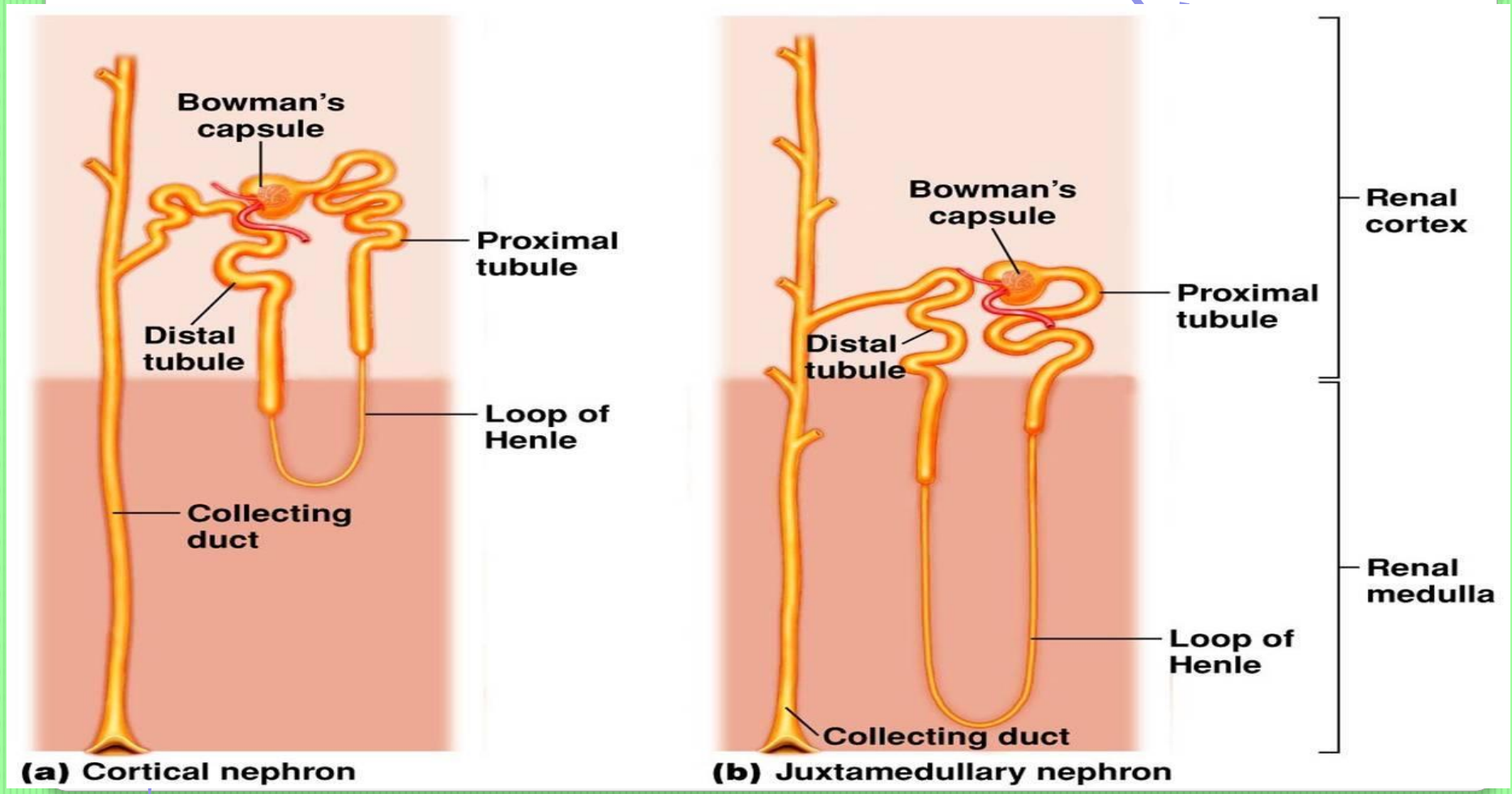

Types of Nephron

2. medullary Nephrons / Juxtamedullary nephrons
= longer Loop of henle, runs deep into medulla

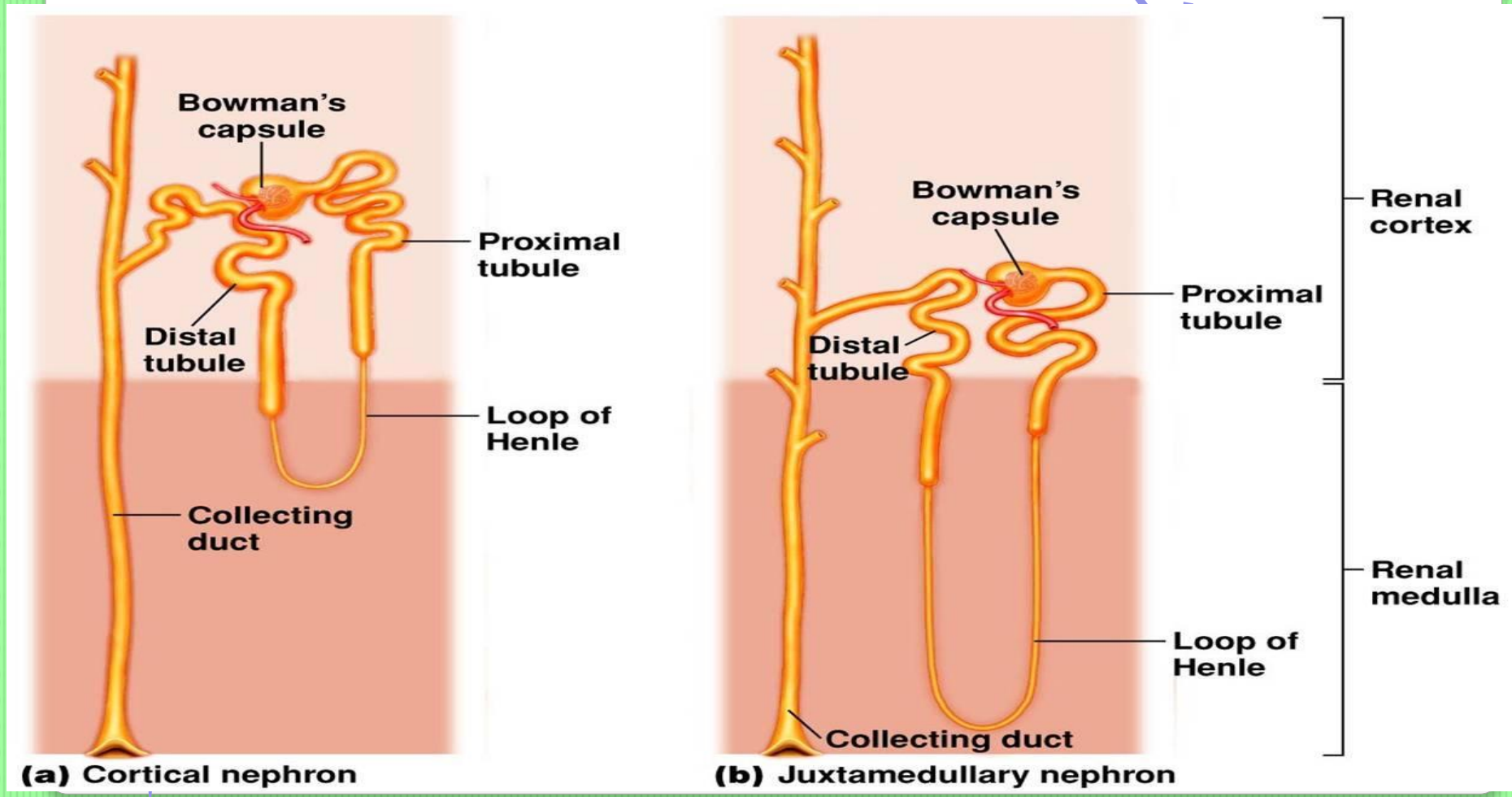

Nephron

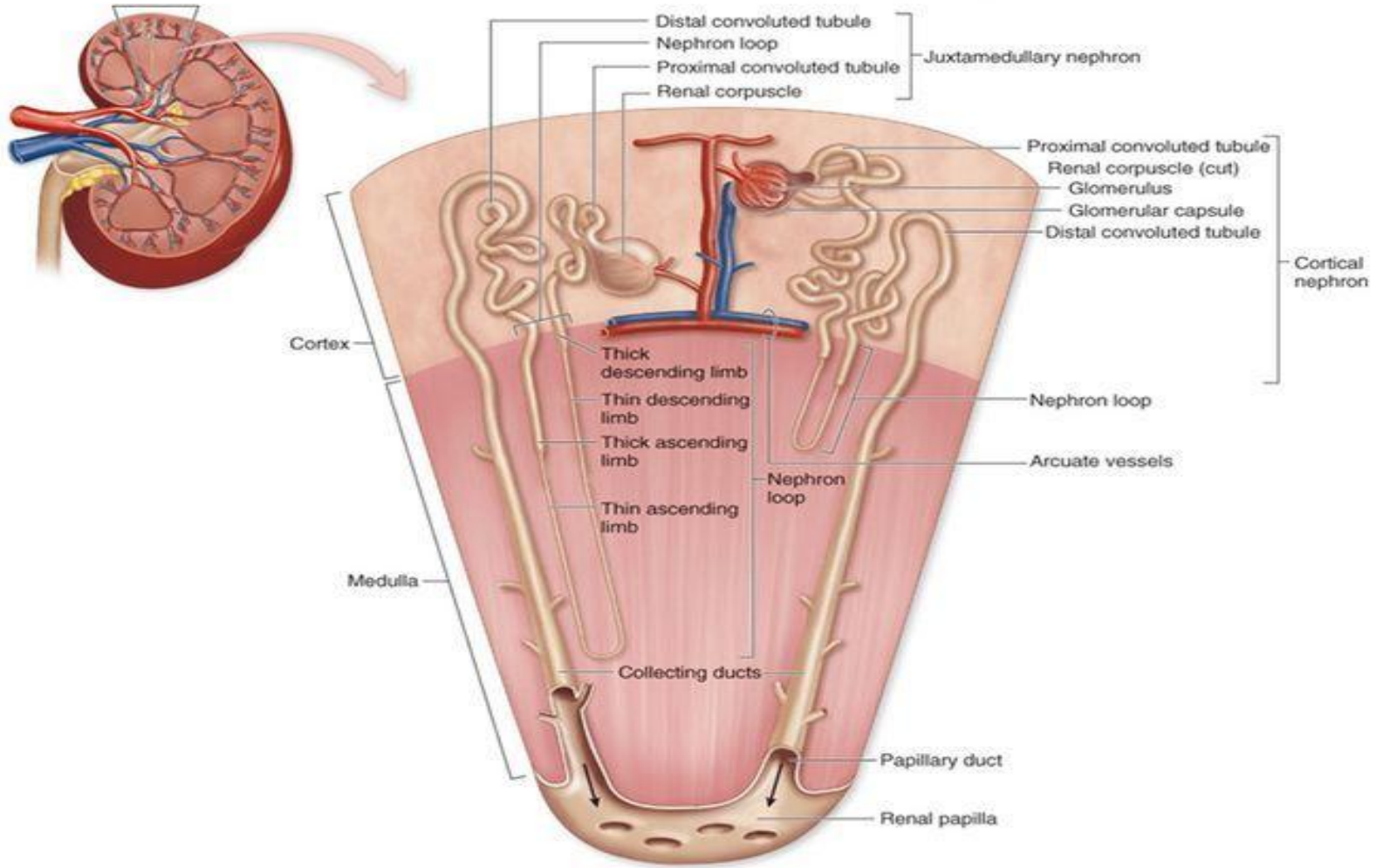
Distal convoluted tubule
Nephron loop
Proximal convoluted tubule
Renal corpuscle
Juxtamedullary nephron
Proximal convoluted tubule
Renal corpuscle (cut)
Glomerulus
Glomerular capsule
Distal convoluted tubule
Cortical nephron
Cortex
Thick descending limb
Thin descending limb
Thick ascending limb
Thin ascending limb
Nephron loop
Arcuate vessels
Nephron loop
Medulla
Collecting ducts
Papillary duct
Renal papilla
image via: pinterest.com

Malpighian corpuscle / renal corpuscle / pygmalion corpuscle.

glomerulus

Bowman's capsule

